

Wegener's Granulomatosis: Autoimmune Disease and Multi-Focal Septal Perforation

Achieving Successful Septal Perforation Repair

Jason S. Hamilton, MD, FACS

Director of the Division of Plastic and Reconstructive Surgery
Osborne Head and Neck Institute, Los Angeles, CA

Ryan Osborne, MD, FACS

Director of the Division of Head and Neck Surgery
Osborne Head and Neck Institute, Los Angeles, CA

Background

Autoimmune disorders are characterized by autoantibodies directed against the patient's body instead of external pathogens (i.e. viruses, bacteria, etc.). In **Wegener's granulomatosis** autoantibodies attack small blood vessels throughout the body, causing swelling and ultimately small inflammatory nodules called granulomas. Granulomas slow blood flow and eventually cut off vital oxygen and nutrients to affected organs causing necrosis (cell death). Small vessels within the nasal cartilage framework are particularly at risk.

Clinical Manifestations

Patients typically present with complaints of increasing nosebleeds and eventually, multiple septal perforations and nasal deformity caused by external cartilage collapse due to poor blood flow.

Medical Considerations

A **Rheumatologist** should evaluate all patients with a history of **Wegener's granulomatosis** who are considering repair of a septal perforations and nasal reconstruction. Patients should be placed on appropriate immunotherapy and the disease should be successfully suppressed before any attempt at reconstructive surgery is made. Co-management with a rheumatologist is crucial.

Surgical Considerations

Successful reconstruction of any part of the body involves removing old scarred tissue and recruiting healthy tissue to rebuild the target area. In patients with Wegener's granulomatosis, the entire septal mucosal lining may have compromised blood flow, and not be healthy enough to use for recruitment and reconstruction of a septal perforation defect. This means that the tissue around the perforation is also affected by Wegener's disease and is unlikely able to tolerate manipulation. These cases typically require a special reconstructive technique. Reconstructive flaps based on the septum mucosal tissue should be avoided to increase the probability of successful closure and healing.

Surgeon Comments

Dr. Hamilton- *"Surgeons choosing to tackle difficult septal perforation cases must have more than one choice technique that they are comfortable with performing. Every case has to be approached uniquely and one technique can't be "stretched" to cover all cases. We have developed new techniques in our practice because it is required to successfully treat a variety of cases. Accordingly, we have been able to achieve a 99% success rate for patients suffering from septal perforations using a customized surgical plan that varies for each patient. Every patient gets his or her own unique procedure."* [Read patient reviews.](#)

Dr. Jason Hamilton is the Director of Plastic and Reconstructive Surgery for the Osborne Head and Neck Institute, and is double board certified by the American Board of Facial Plastic and Reconstructive Surgery and the American Board of Otolaryngology/Head and Neck Surgery. Dr. Hamilton is one of only handful of septal perforation specialist worldwide.

For more information on the deviated septum, septoplasty, functional rhinoplasty and septal perforation repair by Dr. Jason Hamilton, septal perforation specialist, please contact the Osborne Head and Neck Institute or visit www.perforatedseptum.com.

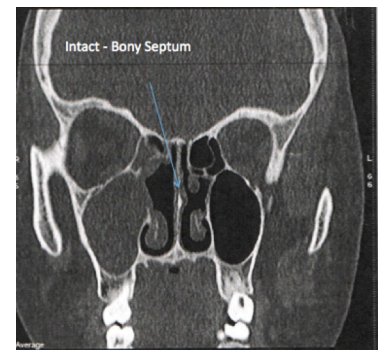
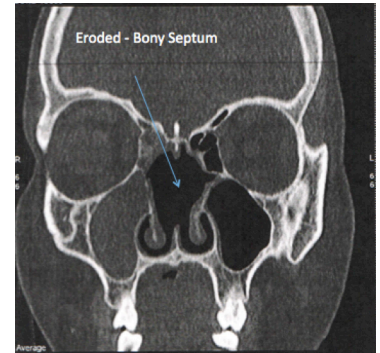


Figure: Late (Top) and early (Bottom) Wegener's Granulomatosis. Wegener's Granulomatosis patient with septal perforation, rhinitis and right maxillary sinusitis. A key feature of Wegener's Granulomatosis associated septal perforation is the propensity for bony destruction. In septal perforations caused by [rhinotillexis](#), [substance abuse](#), [batteries](#), [trauma](#), or prior septoplasty there typically is no extension of the septal perforation beyond the cartilaginous septum. A hallmark of Wegener's Granulomatosis is the extension of the septal perforation beyond the cartilaginous septum into the bony perpendicular plate of the nasal septum.

Editor In Chief:
Alex Fernandez, MS

Corresponding Author:
Jason Hamilton, MD, FACS

Osborne Head and Neck Institute

8631 W. Third Street, Suite 945E
Los Angeles, CA 90048

T: 310-657-0123 (United States)
F: 310-657-0142 (United States)

www.ohni.org